

The Pre-Expanded Scapular Flap: A New Application in the Reconstruction of Post-Burn Contracted Neck

ABDEL-MOHSEN ABOU EL-DAHAB, M.D.; ABDEL-FATTAH M. ABDALLAH ABDEL-FATTAH, M.D. and HUSSAIN SABER ABULLHASSAN, M.D.

The Department of Plastic and Reconstructive Surgery, Faculty of Medicine, Alexandria University.

ABSTRACT

Burn contracutures greatly affect the patient both psychologically and functionally. Restoration of the function as well as appearance requires adequate release of contracted and distorted mentocervical relation, followed by appropriate resurfacing technique. In the present study, eight patients suffering from severely contracted neck as sequelae of full thickness burn were managed by the use of a pedicled pre-expanded scapular flap. All patients showed good and encouraging results and the technique proved to be easy, reliable but time consuming to some extent. So, pre-expansion of the scapular flap has extended the clinical applications of this very versatile flap and allowed the coverage of large skin defects.

INTRODUCTION

Mentocervical and mentocervico-thoracic burn sequelae traditionally have been treated by liberation and resurfacing with free skin grafts or local flaps [1,2,3]. Microsurgical techniques have recently allowed free tissue transfer for treatment of this difficult problem [4]. Different types of flaps have been described in the literature for resurfacing of the contracted neck after resection of the burn scar [5,6]. Since Fonesca dos Santos described the anatomy of the scapular flap [7], Gilbert used it as a free flap [8] and Nassif et al. [9] presented an anatomic study and the clinical free transfer of a parascapular flap, many clinical applications of scapular and parascapular flaps have been reported [10-14].

Depending on the cutaneous transversing and descending branches of circumflex scapular vessels, the scapular flap is designed horizontally and the parascapular flap is designed vertically [10-14].

The scapular area has become the favorite flap donor site since the description of the latissimus dorsi flap, the scapular and parascapular flaps [9,15,16]. The sub scapular pedicle is the dominant

blood supply to the skin covering the back and lateral chest wall. The anatomy of the latissimus dorsi, scapular and parascapular flaps has been well documented in the literatures [9,17-22].

Leighton et al. [23], demonstrated in pigs that fasciocutaneous flap expansion prior to transfer increases the area of skin that can be safely elevated on a single vascular pedicle. Blood flow through the pedicle into an enlarged vascular tree was greatly increased following expansions in the pig model with thinning of the overlying soft tissue and complete survival of the flaps [24].

We performed expansion of the scapular flap prior to transfer in eight patients for reconstruction of severely contracted burned neck.

The aim of the present work was to extend the clinical applications and usefulness of the scapular flap in reconstruction of severely burned neck contracture.

PATIENTS AND METHODS

Eight patients, 6 females and 2 males, of different ages (30-50 years) with severe degree of post burn contracted neck, were treated in the Plastic and Reconstructive Surgery Unit of Alexandria Main University Hospital in the period from January 2001 to December 2002. The deformity consisted of wide spread, massive keloidal scarring resulting in conspicuous disfiguring and incapacitating degree of cervicomental obliteration.

First stage (placement of the expander):

A preliminary approach to roughly estimate the size of the skin flap needed to cover the raw area

of the neck after release. It had been better to make the expanded flap larger than the proposed defect. This pattern was then placed over the area of the scapular donor site, orienting the marked position and direction of the vascular pedicle to the location of the circumflex scapular axis (Fig. 1).

The superior edge of the proposed skin flap as drawn on the back served as the incision for placement of tissue expander. The incision was made down to the superficial muscle fascia. A pocket has been developed beneath the fascia, the expander was placed on top of the underlying latissimus dorsi and serratus muscles. The filler valve should be tunnelled into a position that could be easily palpated and the connecting tube left long enough to prevent valve displacement during expansion.

Expansion was begun 14 days later with 70-100 ml of normal saline added twice weekly with 3-4 days interval as tolerated by the patient and stopped shortly of causing blanching of the overlying flap site. Over expansion was mandatory to provide sufficient tissue for coverage of the cervical defect and at the meantime would allow direct closure of the donor site (Fig. 2).

Second stage:

Three to four months later or after one month of the over expansion. The contracted scar has been surgically excised under general anaesthesia while the patient was placed in the supine position. The excision has always included the contracted platysma muscle which would therefore entailed reaching down to the deep investing layer of cervical fascia. This has been to release the obliterated cervicomen- tal contracture leaving a neck normally contoured and lengthened. Meticulous haemostasis should be carried out (Fig. 3). Then the patient was turned to the lateral side nearer the flap donor sit, with the arm slightly flexed and elevated above the head to open the axilla. Marking of the expanded scapular flap was carried out.

The pattern again is oriented over the expanded skin and the flap elevated making the previous implant placement incision the superior border of the flap. A wide cuff of soft tissue was included as the dissection proceeds toward the vascular pedicle to protect the expanded branches of the vascular tree (Fig. 4) [24]. The pedicle is usually traced through the triangular space to the subscapular vessels that will be the axis of rotation (Fig. 4).

The capsule of the expander should be left attached to the undersurface of the flap, while the capsule beneath the expander on the surface of the underlying muscles can be left intact. Further undermining of the surrounding skin edges facilitates tensionless closure. The flap was then tunneled through the axilla to reach the neck (Fig. 4).

In order to make the flap cover the whole defect without putting too much tension on the pedicle, the flap must pass under the thoracodorsal nerve and latissimus dorsi muscle at its insertion (Fig. 4). Also, the inferolateral border of the pectoralis major muscle needed to be cut by diathermy to create a groove where the pedicle would settle down easily instead of bridging over the border that might add some unnecessary tension on the pedicle. This step would also have the added advantage of increasing the reach of the flap (Fig. 5).

The patient would then be returned to supine position to inset the flap in the newly created normally shaped neck (Figs. 6 & 7) and dressings would then be applied so as to maintain the newly created mento-cervico-thoracic angle.

RESULTS

Six females and 2 males of ages ranging from 25 to 55 years with an average of 40 have been treated in this series. Expander capacity used in each case was 1000 ml and the number of expanders used was one for each case. The expansion period was in the average of 3 months reaching an over expansion of up to 1300 cc-1500 ml.

All flaps have been successfully moved into the neck to cover the defect after release of the contracture and regaining of the cervicomen- tal relation. Expansion, with the aforementioned over-expansion has been successful and uneventful in all cases (8 cases) of the series.

The flap size ranged from 25-32 x 16-20 cm with a maximum size of 32 x 20 cm. All flaps were thinned by the expansion process, no flap losses or necrosis were encountered in our patients.

All donor sites healed uneventfully except one patient where partial wound dehiscence developed and healed by secondary intention. However, a small piece of split skin graft was used in one patient to cover part of the defect over the chest wall after release of the contracture (Figs. 8: A-J & 9: A-D).

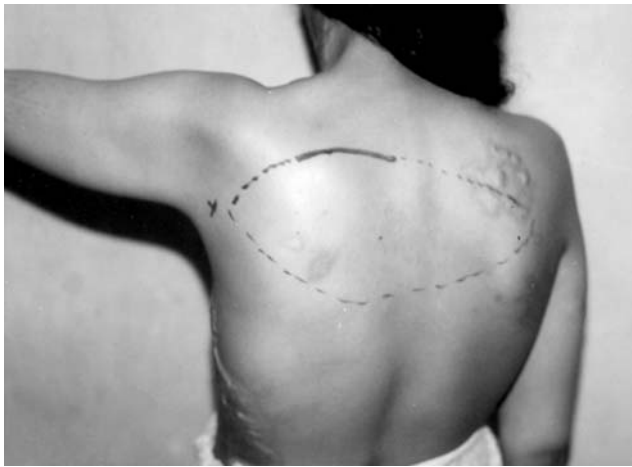

Fig. (1): 30-years old female with post-burn contracted neck the flap is designed (dotted line) and the incision for placement of expander (continuous line).

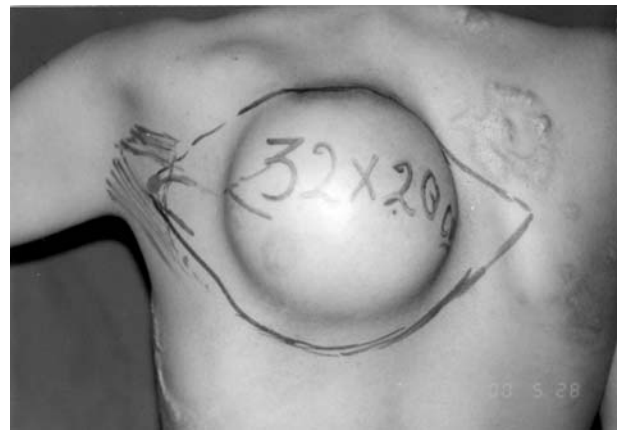

Fig. (2): The same patient showing maximal expansion.

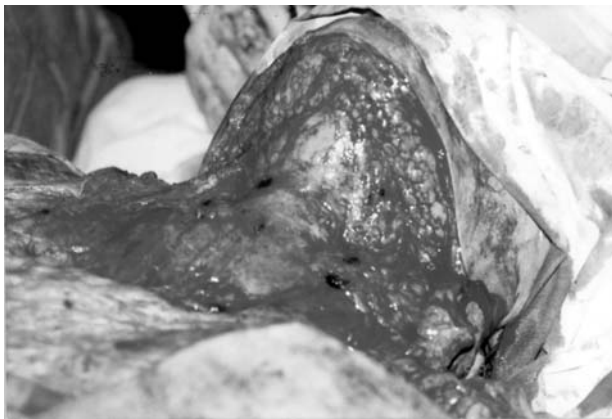

Fig. (3): Intra-operative view after excision of the scarred skin, platysma and neck release.

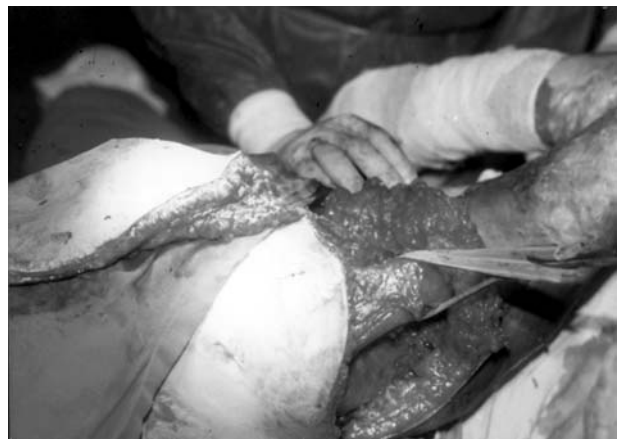

Fig. (4): Intra-operative view after opening the axilla, raising the head of latissimus dorsi near its insertion, tunneling of the flap (just beside the rubber drain).
Note: The cuff of soft tissue around the vascular pedicle.

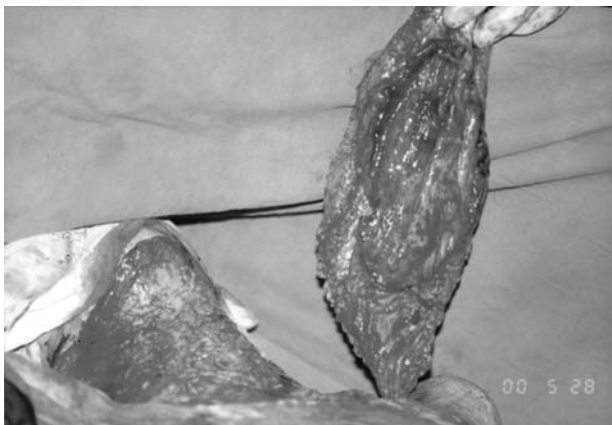


Fig. (5): Intra-operative view after tunneling of the flap without tension on the pedicle.



Fig. (6): Intra-operative view with the pre-expanded scapular flap covering the neck defect.

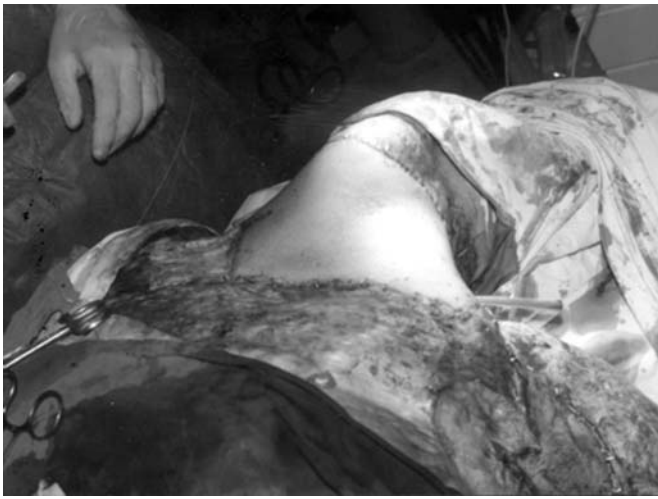

Fig. (7): Immediate post operative with the flap covering the neck defect except small area covered by split graft.

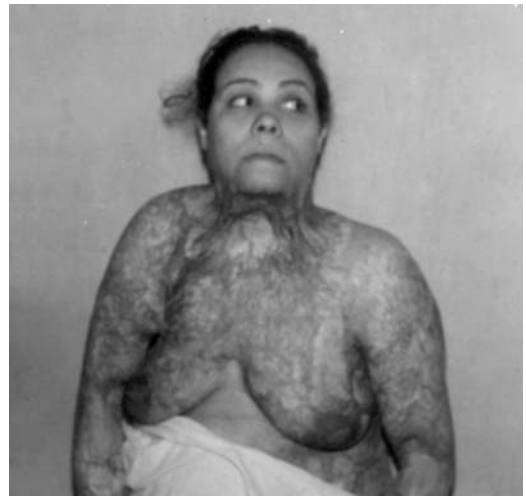

Fig. (8-A): 35-years female with severe post burn contracted neck, scar chest and arms.

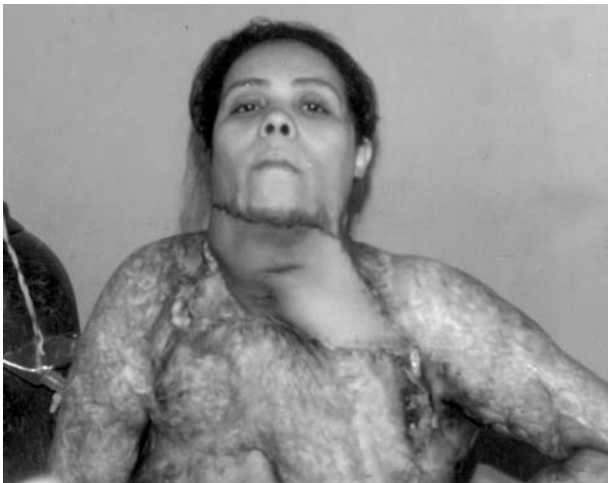

Fig. (8-B): Anterior view 2 weeks post operative.

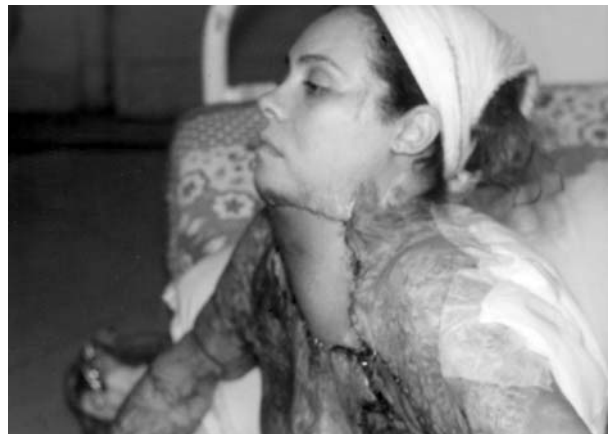

Fig. (8-C): Left lateral view 2 weeks post operative.

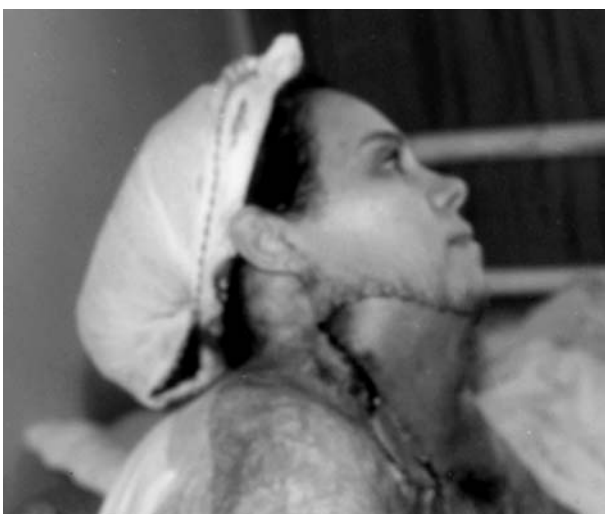

Fig. (8-D): Right lateral view 2 weeks post operative.

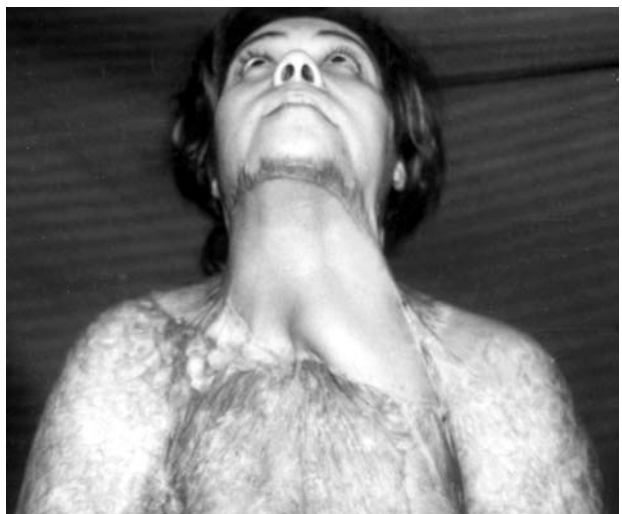


Fig. (8-E): Late post operative anterior view.

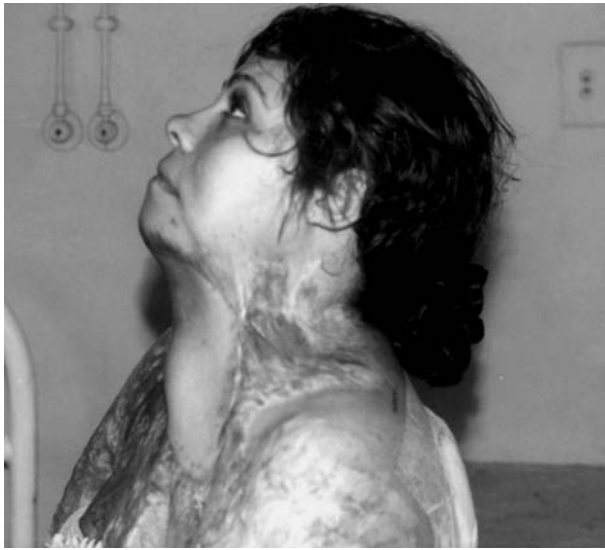

Fig. (8-F): Late post operative left lateral view.

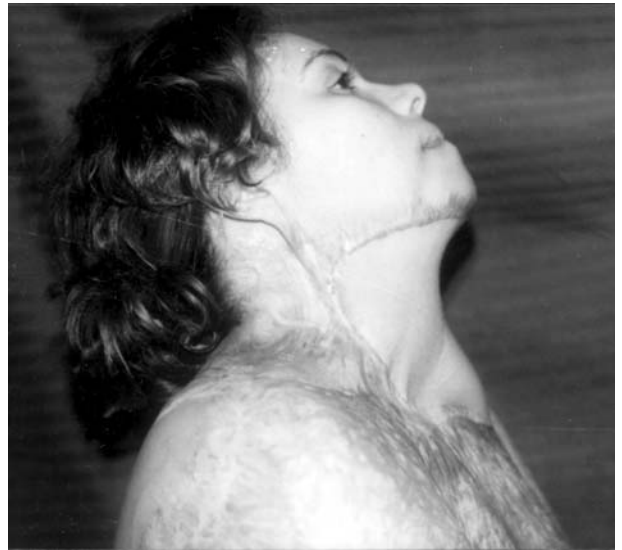

Fig. (8-G): Late post operative right lateral view.

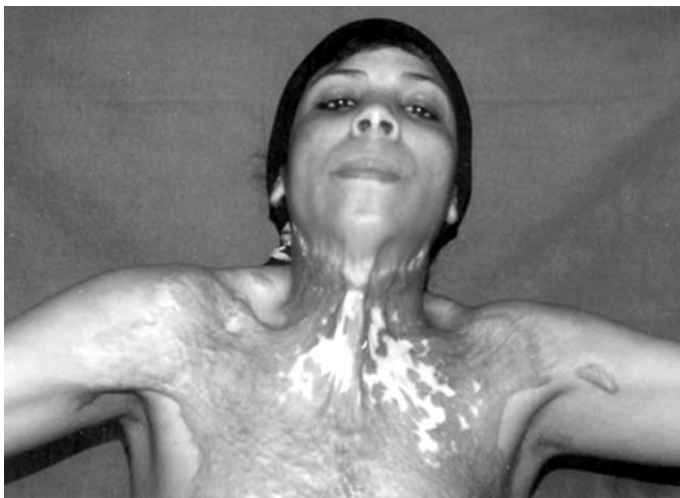

Fig. (9-A): Pre-operative anterior view of 40 years female with post burn contractive scar, neck and chest.

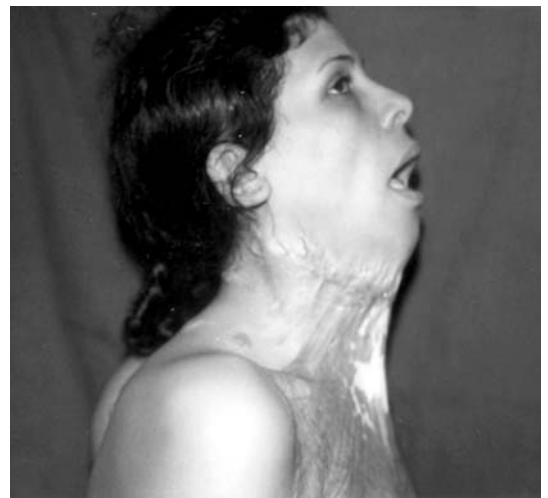

Fig. (9-B): Pre-operative: right lateral view.

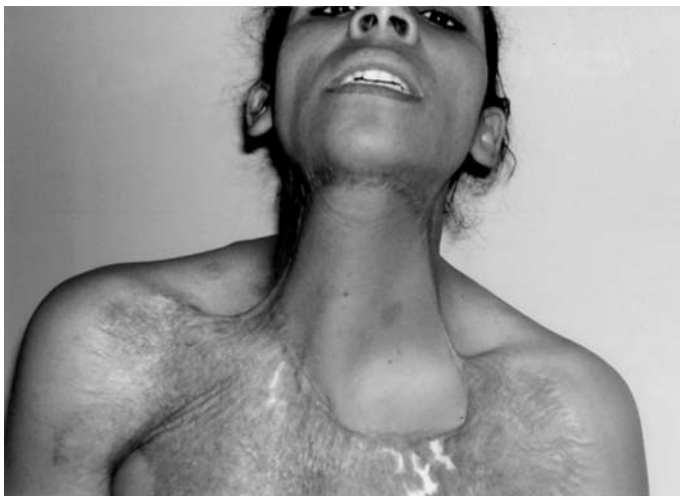

Fig. (9-C): Late post operative: anterior view.

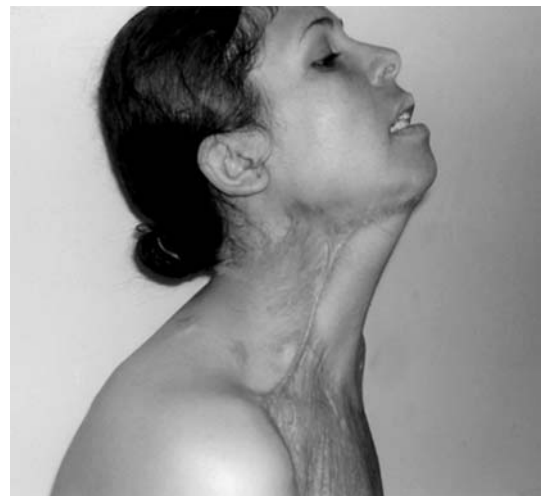

Fig. (9-D): Late post operative: right lateral view.

DISCUSSION

Resurfacing of the anterior neck with free tissue transfer is preferable to skin grafting or local flaps. A skin graft requires a splinting period wearing a neck brace and recurrence of the contracture still often occurs. Local flaps usually require delay procedures and it is impossible to reconstruct the whole aesthetic unit of the anterior neck with one local flap [25].

The scapular, parascapular and ascending scapular flaps, based on the cutaneous horizontal, descending and ascending branches of the circumflex scapular vessels, have the advantage of a long, large and constant pedicle, thin and hairless skin and primary closure of the donor site without significant cosmetic or functional sequelae. The small size of the unexpanded scapular flap (range from 11-15 x 6-10 cm) makes it unsuitable for covering large defects and there is also much more tension in a horizontally oriented flap than in a vertical flap in obtaining primary closure [26]. The expanded scapular flap solved these problems and allowed good coverage as well as primary closure of the donor site.

Scapular flap expansion produced thinning in all cases, improving the final contour after transfer. Experimentally and clinically, thinning takes place almost entirely in the dermis and subcutaneous fat layer [24,27-29]. There appears to be generation of new tissue except in the epidermal layers. The donor sites could be closed primarily in all patients with linear scar.

Clinically expanded tissue appears to be less elastic than normal unexpanded skin and will not stretch as far under the same tension. The surgeon must therefore expand the area enough to obtain a flap of the desired dimensions to allow sufficient remaining skin for primary donor site closure [30]. So, the flap should be drawn larger than desired and over expansion is recommended in all cases. In the present study, over-expansion was the rule in all cases reaching up to 300-500 cc saline above the expander capacity. This advantage allowed the coverage of large neck defects after full release as well as linear donor site closure with undue tension in almost all the cases.

The incision for expander placement should be made superior or superolateral to the intended pocket on the chest wall. Inferiorly placed incisions could become disrupted, therefore exposing the expander [30]. In our group we have not met exposure of the

expander in any case as we placed the incisions superiorly.

In this series the filling ports were placed over the acromion for ease of identification, other authors used the lateral chest wall over a rib. In our cases we placed the filling port over the acromion and there was no difficulty in identification during the expansion. The tubing connecting the filling port to the expander should be left loose to allow for some movement toward the expander as it is filled. This prevents displacement of the filling port during expansion [30].

A single tissue expander was placed in all the patients in a subfascial plane directly beneath the cutaneous branches of the circumflex scapular artery. Leighton et al. [23] noted histologically that flap expansion in an experimental pig model increased the number of vessels in a given area of tissue and greatly expanded the entire vascular tree in axial-pattern buttock flap [23-24].

Expansion and delay of known axial-pattern flaps is one of the new methods of flap prefabrication that increase the usefulness of established flaps [31]. Scapular flap expansion prior to transfer requires two surgical procedures and necessitates a time investment by both the patient and the surgeon. The patient must be informed of all possible complications that can occur with expander placement, the necessity of two operative procedures and the inherent risk of flap failure if free tissue transfer is performed. Despite these inconveniences, donor-site expansion prior to transfer may offer the best reconstructive option in selected patients. Not only can a flap be created, but the entire back tissue across the midline up to the contralateral shoulder can be elevated after expansion and delay on a single vascular pedicle, to resurface large defects.

Scapular flap should be considered in special circumstances where a thin and/or very large cutaneous flap is required for coverage or contour restoration [30].

The advantages of the expanded scapular flap:

- 1- It is an axial fasciocutaneous flap which renders it versatile and reliable.
- 2- Expansion makes it suitable for coverage of large defects whether as a pedicled or free transfer. In this series the size of the expanded flap ranged from (25-32 x 16-22 cm) which is three to four times the size of a similar unexpanded scapular flap.

- 3- It is technically easy to raise and transfer.
- 4- The overlying skin is thin and hairless in females.
- 5- Minimal donor site morbidity.
- 6- It is readily accessible, being adjacent to the operative field of the resection [32].

Our clinical experience with pedicled expanded scapular flap for the repair of post burn severely contracted neck has proved the reliability, versatility of this prefabricated flap to cover large defects. These features extended the application of the scapular flap as a pedicled one with high rate of success, short operative time and no adverse complications of the microsurgically transferred flaps.

REFERENCES

- 1- Aufricht G.: Evaluation of pedicle flaps versus skin grafts in reconstruction surface defects and scar contractures of the chin, cheeks and neck. *Surgery*, 15: 75, 1944.
- 2- Cronin T.D. and Barrera A.: Deformities of the cervical region. In: J. C McCarthy (Ed.) *Plastic Surgery*. Philadelphia: Saunders, pp 2057-93, 1990.
- 3- Moustafa M.F.H., Borhan A. and Abdel-Fattah A.M.A.: Burn contractures of the neck. *Plast. Reconstr. Surg.*, 62: 66, 1978.
- 4- Harii K., Ohmori K. and Ohmori S.: Utilisation of free composite tissue transfer by microvascular anastomosis for the repair of burn deformities. *Burns*, 1: 237, 1975.
- 5- Kobus K. and Stepniweski J.: Free flaps versus conventional surgery. *Am. J. Plast. Surg.*, 15: 14, 1985.
- 6- Tizian C. and Berger A.: Rekonstruktion der halskontur nach verbrennungen mit mikrochirurgischen technik. *Hand Chir, Mikrochir Plast. Chir.*, 17: 255, 1985. Cited in reference number 25.
- 7- Dos Santos F.: Retalko escapular: um novo retalholivres microcirurgio. *Rev. Bras Cir.*, 70: 133, 1980. Cited in reference number 26.
- 8- Gilbert A.: Le lambeau scapulaire. *Cinquieme Recontre International de Micro Chirurgie 1980*. Cited in reference number 26.
- 9- Nassif T.M., Vidal L., Bovet J.L., et al.: The parascapular flap: A new cutaneous microsurgical free flap. *Plast. Reconstr. Surg.*, 69: 591, 1982.
- 10- Hamilton S.G. and Morrison W.A.: The scapular free flap. *Br. J. Plast. Surg.*, 35: 2, 1982.
- 11- Mayou P.J., Whitby D. and Jones B.M.: The scapular flap: An anatomical and clinical study. *Br. J. Plast. Surg.*, 35: 8, 1982.
- 12- Swartz W.M., Banis J.L., Newton E.D., et al.: The osteocutaneous scapular flap for mandibular and maxillary reconstruction. *Plast. Reconstr. Surg.*, 77: 530, 1986.
- 13- Chen D., Jupiter J.B., Lipton H.A., et al.: The parascapular flap for treatment of lower extremity disorders. *Plast. Reconstr. Surg.*, 84: 108, 1989.
- 14- Coleman J.J. and Sultan M.R.: The bipedicled osteocutaneous scapular flap. A new subscapular system free flap. *Plast. Reconstr. Surg.*, 87: 682, 1991.
- 15- Maxwell G.P., Stewber K. and Hoopes J.E.: A free latissimus dorsi myocutaneous flap. *Plast. Reconstr. Surg.*, 62: 462, 1978.
- 16- Gilbert A. and Teot L.: The scapular flap. *Plast. Reconstr. Surg.*, 69: 601, 1982.
- 17- McCraw J.B., Dibbel D.G. and Canaway J.W.: Clinical definition of independent myocutaneous vascular territories. *Plast. Reconstr. Surg.*, 60: 341, 1977.
- 18- Mathes S.J. and Nahai F.: Classification of the vascular anatomy of muscles: experimental and clinical correlation. *Plast. Reconstr. Surg.*, 67: 177, 1981.
- 19- Mathes S.J. and Nahai F.: Posterior trunk. In: K. Berger (Ed). *Clinical application for muscle and musculocutaneous flaps*. St. Louis, Mosby, Chap 16, pp 341-8, 1982.
- 20- Barwick W.J., Goodkind D.J. and Serafin D.: The free scapular flap. *Plast. Reconstr. Surg.*, 69: 779, 1982.
- 21- Dos Santos L.F.: The vascular anatomy and dissection of free scapular flap. *Plast. Reconstr. Surg.*, 73: 599, 1984.
- 22- Kon M.: The parascapular flap. *Neth. J. Surg.*, 40 (3): 80, 1988.
- 23- Leighton W.D., Russell R.C., Marcus D.E., et al.: Experimental pretransfer expansion of free flap donor site: I Flap viability and expansion characteristics. *Plast. Reconstr. Surg.*, 82: 69, 1986.
- 24- Leighton W.D., Russell J.R., Feller A.M., et al.: Experimental pretransfer expansion of free flap donor site: II Physiology, Histology and clinical correlation. *Plast. Reconstr. Surg.*, 82: 76, 1988.
- 25- Angrigiani C.: Aesthetic microsurgical reconstruction of anterior neck burn deformities. *Plast. Reconstr. Surg.*, 93 (3): 507, 1994.
- 26- Xu J., Li S.K., Li Y.Q., Ma X.B. and Li S.Y.: Superior extension of the parascapular free flap for cervical burn scar contracture. *Plast. Reconstr. Surg.*, 96 (1): 58, 1995.
- 27- Pasyk K.A., Austad E.D., McClatchey K.D., et al.: Electron microscopic evaluation of the guinea pig skin and soft tissue "expanded" with a self-inflating silicon implant. *Plast. Reconstr. Surg.*, 70: 37, 1982.
- 28- Austad E.D., Pasyk K.A., McClatchey K.D., et al.: Histomorphologic evaluation of guinea pig skin and soft tissue after controlled tissue expansion. *Plast. Reconstr. Surg.*, 70: 704, 1982.
- 29- Reali M., Chiarugi C., De Siena G. and Giannotti V.: Sonographic evaluation of dermis and subcutaneous tissue during and after skin expansion. *Plast. Reconstr. Surg.*, 93: 1050, 1994.
- 30- Russell R.C., Khouri R.K., Upton J., et al.: the expanded scapular flap. *Plast. Reconstr. Surg.*, 96 (4): 884, 1995.
- 31- Khouri R.K., Upton J. and Shaw W.W.: Principles of flap prefabrications. *Clin. Plast. Surg.*, 19: 763, 1992.
- 32- Gopinath K.S., Chandrshekar M., Kumar M.V. and Bhargava A.: The scapular fasciculated flap: A new flap for reconstruction of the posterior neck. *Br. J. Plast. Surg.*, 46: 508, 1993.